

# Fractional 1320 nm Nd : YAG laser in the treatment of acne vulgaris: a pilot study

Hui Deng<sup>1</sup>, Ding-Fen Yuan<sup>1</sup>, Chun-Lin Yan<sup>2</sup> & Xu-An Ding<sup>1</sup>

<sup>1</sup>Department of Dermatology, The Sixth People's Hospital of Shanghai, Shanghai Jiaotong University, Shanghai, China, and <sup>2</sup>Department of Dermatology, Parkwayhealth China, Shanghai, China

## Summary

### Key words:

acne vulgaris; fractional 1320 nm Nd : YAG laser

### Correspondence:

Hui Deng, Department of Dermatology, The Sixth People's Hospital of Shanghai, Shanghai Jiaotong University, Yishan Road 600, Shanghai 200211, China.

e-mail: denghui\_1@hotmail.com

### Accepted for publication:

27 May 2009

### Conflicts of interest:

None declared.

Thirty-five patients with moderate to severe acne were treated with a fractional 1320 nm neodymium : yttrium aluminum garnet (Nd : YAG) laser. These patients received six treatment sessions at a 2-week interval. Inflammatory and non-inflammatory lesions were counted before and after treatment. Fractional 1320 nm Nd : YAG laser therapy was well tolerated, resulting in the reduction of inflammatory lesions by 57% ( $P < 0.05$ ) and the reduction of non-inflammatory lesions by 35% ( $P < 0.05$ ). A significant reduction in the skin sebum level by 30% ( $P < 0.05$ ) was also noted after treatment.

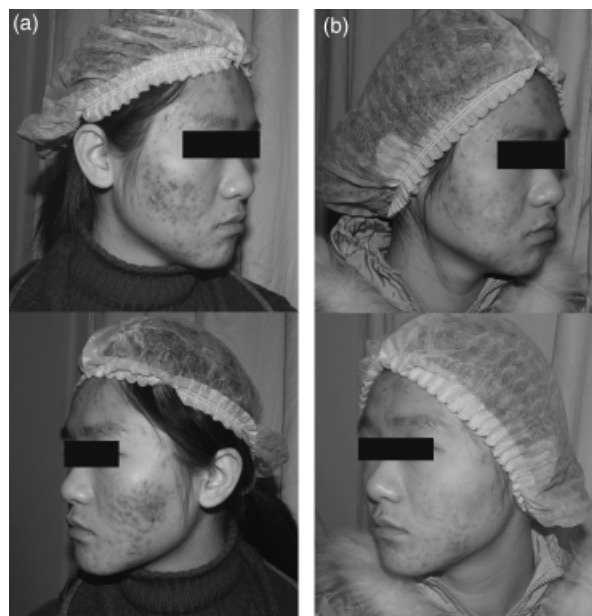
Acne vulgaris is a common skin condition, affecting over 85% of people. Because of its effect on quality of life, acne vulgaris is more than a merely physiological or cosmetic entity. Acne is caused by changes in the pilosebaceous units. Patients have excess sebum production and non-inflammatory follicular papules. Proliferation of *Propionibacterium acnes* may lead to the formation of inflammatory papules, pustules, nodules and cysts. Topical and systemic drugs have been successfully used in the treatment of acne. However, many people are concerned about the side effects of these medicines, especially younger patients.

Recent reports demonstrated that sequential treatment with laser- and light-based devices lead to a clinical improvement in acne. The rapid clearance of acne lesions is particularly of interest to patients and physicians. These devices include a 532 nm potassium titanyl phosphate laser, a 585 nm pulsed dye laser, a 1450 nm diode laser, a 1540 nm Er : glass laser, a 1320 nm Nd : YAG laser, blue light and photodynamic therapy. We performed an open study of fractional 1320 nm Nd : YAG laser as phototherapy of acne vulgaris. This treatment was shown to be effective and well tolerated by patients.

## Methods

Patients (age 25–33 years; Fitzpatrick skin type I–IV) with moderate to severe acne vulgaris were treated with a fractional 1320 nm Nd : YAG laser (Harmony, Almar Lasers Ltd, Caesarea,

Israel). A topical lidocaine cream was applied on the face 30 min before the treatment. Fluencies of 10–15 J/cm<sup>2</sup> at densities of 25 MTZ/cm<sup>2</sup> were applied on acne lesions in five to six passes. Ice



**Fig. 1.** Patients treated with a fractional 1320 nm Nd : YAG laser: (a) before the first treatment and (b) 6 months after the last treatment.

**Table 1.** Effects of fractional 1320 nm Nd : YAG laser on the lesion accounts and sebum level

	Inflammatory lesions		Non-inflammatory lesions		Sebum level	
	Mean	Reduction (%)	Mean	Reduction (%)	Mean	Reduction (%)
Baseline	27 ± 8		223 ± 46		32 ± 9	
6 weeks	18 ± 7 <sup>#</sup>	33 ± 6	186 ± 28 <sup>#</sup>	16 ± 3	28 ± 7 <sup>#</sup>	13 ± 5
12 weeks	11 ± 5 <sup>#</sup>	57 ± 5	143 ± 32 <sup>#</sup>	35 ± 5	22 ± 4 <sup>#</sup>	30 ± 4
24 weeks	8 ± 3 <sup>#</sup>	69 ± 4	165 ± 28 <sup>#</sup>	26 ± 7	16 ± 5 <sup>#</sup>	49 ± 7

<sup>#</sup>P < 0.05 versus baseline.

pack cooling was used before and immediately after the laser treatment. Six treatment sessions at 2-week interval were performed on affected area. Patients were clinically assessed at baseline, before each treatment and 12 weeks after the sixth treatment (Fig. 1). Evaluations included formal counts of inflammatory and non-inflammatory lesions. Comedones are considered as non-inflammatory lesions. Erythematous papules, pustules, nodules and cysts are considered as inflammatory lesions. Sebum excretion was registered in all patients before treatment and at every follow-up visit. Patients were instructed not to wash or use any emollient for 12 h before every visit. The sample was taken from the same spot 3 cm lateral to the alar rim on both cheeks every time. This spot was treated in the same way as acne lesions with a laser. A Sebumeter SM-815 (Courage-Khazaka, Koln, Germany) was used. Physicians evaluated side effects such as erythema, edema, hyper- or hypo-pigmentation. The level of pain was assessed by patients immediately after treatment. This study has been reviewed and approved by the institutional review board in The Sixth People's Hospital of Shanghai. Data were collected and analyzed by one-way ANOVA. The  $\alpha$ -level was 0.05.

## Results

Forty-one patients were included in this study; 35 patients completed six treatment sessions. The number of lesions at different visits is shown in Table 1. A reduction in the number of lesions from baseline was noted after three treatments. Inflammatory papules, nodules and cysts responded better to the treatment, with a reduction of 57% (from 27 ± 8 at baseline to 8 ± 3) after six sessions of treatment. Non-inflammatory comedones also responded well to the treatment. Fractional 1320 nm Nd:YAG laser can inhibit sebum production. The skin sebum level decreased 30% after six treatments. During a follow-up period of 12 weeks, we found that the effect of laser therapy lead to a relatively long-term remission for acne lesions and reduction of skin sebum production. Patients tolerated moderate and transient pain well

in this study. Erythema lasting about 3 days was encountered by all the patients. No patients reported persistent edema or pigmentation changes.

## Discussion

Dermatologists have attempted the use of different light and laser treatments on acne. Natural light and artificial blue light has been reported to kill *P. acnes*. Several laser systems have been shown to destroy sebaceous glands, including near-infrared lasers and radiofrequency devices (1). Orringer et al. conducted a split-face clinical trial on 46 patients using a 1320 nm Nd : YAG laser. A transient but statistically significant improvement in the lesion counts of open comedones was demonstrated in treated skin as compared with untreated skin (2). Traditional infrared lasers may cause damage to the epidermis at an energy high enough to destroy the sebaceous gland. Fractional photothermolysis is a new concept using infrared light, which can elicit an array of microscopic thermal injuries at controllable depths in the dermis, limiting the damage to the treated area and accelerating the rate of epidermal repair (3). In our clinical research, the fractional 1320 nm Nd : YAG laser reduced both the lesion number and sebum excretion after six treatments. We can use a higher fluency and a shorter treatment interval than the traditional 1320 nm Nd : YAG laser (3). No severe side effects were found in the study with application of ice pack cooling. In conclusion, the fractional 1320 nm Nd : YAG laser is effective and safe in the treatment of acne vulgaris.

## References

1. Munavalli GS, Weiss RA. Evidence for laser- and light-based treatment of acne vulgaris. *Semin Cutan Med Surg* 2008; **27**: 207–211.
2. Orringer JS, Kang S, Maier L, et al. A randomized, controlled, split-face clinical trial of 1320-nm Nd:YAG laser therapy in the treatment of acne vulgaris. *J Am Acad Dermatol* 2007; **56**: 432–438.
3. Jih MH, Kimyai-Asadi A. Fractional photothermolysis: a review and update. *Semin Cutan Med Surg* 2008; **27**: 63–71.